

**American College of Physicians - Internal Medicine Meeting 2025  
New Orleans, LA**

**Arthrocentesis and Bursal Injection**

**Faculty Information**

***Director:***

**Eric J. Anish, MD, FACS**

**Simrun Bal, MD, Member**

**Diego Cahn-Hidalgo, MD, FACP**

**Paul F. Howard, MD, MACP, FACR**

**Kevin J. Kempf, MD, FACP, FACR**

**Hani Rashid, DO, Member, FACR**

**Trent H. Smith, MD, Member**

**Catherine Chiu Tan, MD**

**Remygrace Sass, MD, Resident/Fellow Member**

Posted Date: February 24, 2025

©2025 American College of Physicians. All rights reserved. Reproduction of presentations, or print or electronic material associated with presentations, is prohibited without written permission from the ACP.

Any use of program content, the name of a speaker and/or program title, or the name of ACP without the written consent of ACP is prohibited. For purposes of the preceding sentence, "program content" includes, but is not limited to, oral presentations, audiovisual materials used by speakers, program handouts, and/or summaries of the same. This rule applies before, after, and during the activity

# Generic Arthrocentesis Procedure

---

## Position the patient in a comfortable position

- Usually recumbent, except for upper extremity arthrocentesis - shoulder, elbow, wrist and carpal tunnel injection
- Position patient for operator comfort

## Identify landmarks for needle insertion

- Mark site with surgical marking pen or make impression with tip of retracted ball- point pen

## Clean skin at injection site

- Clean 3 times with povidone-iodine solution
  - a) Begin in center of area to be cleaned, wiping in widening spirals to periphery
  - b) Clean area 5 cm in diameter
  - c) Allow to dry for 1 minute
  - d) Wipe area of needle insertion one time with alcohol sponge

## Prepare and administer anesthetic

- Draw up 3 mL of lidocaine in a 3 mL or 5 mL syringe
- Using 25-gauge needle, make wheal at the marked injection site
- Direct needle towards joint
- Inject remainder of lidocaine along path to joint capsule
- An alternative or an adjunct to injecting lidocaine is ethyl chloride sprayed at the site of needle insertion

## Entering joint space

- Prepare aspirating syringe with 18 or 20-gauge needle
  - a) Select syringe size that will be adequate for amount of effusion
  - b) 20 mL syringes commonly used for knee
- Pull back on plunger of syringe to "break the bead" to ensure smooth and easy operation when in joint
- Direct needle through anesthetic wheal toward joint, using firm, confident motion
- "Popping" sensation can often be felt when joint capsule penetrated

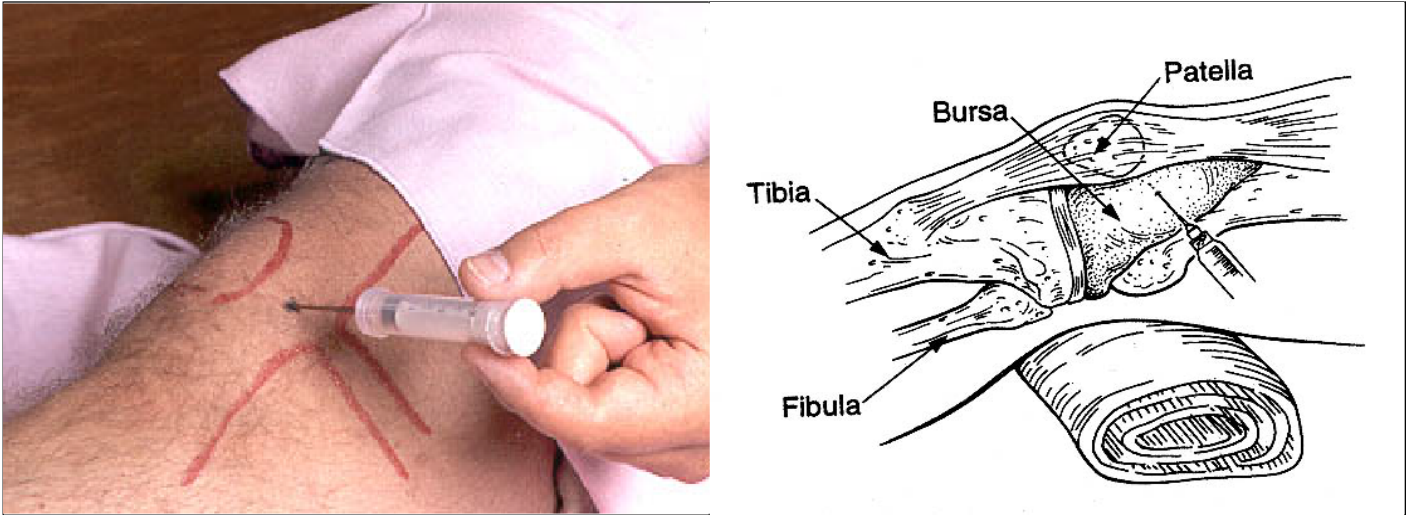
## Aspirating joint fluid

- Stabilize needle with non-dominant hand
  - a) Hold hub of needle with thumb and index finger
  - b) Rest heel of hand against patient
- Gently aspirate fluid

## Ending the procedure

- Smoothly withdraw needle and syringe as one unit
- Apply firm pressure to arthrocentesis/injection site with gauze sponge
- Clean off excess povidone-iodine with alcohol
- Apply Band-Aid to needle insertion site
- Option for injecting medication
  - a) Gently remove syringe with smooth twisting motion
  - b) Attach syringe with medication

# Arthrocentesis of the Knee



## 1. Identify the Injection Site

- Locate superior and inferior pole of the patella, divide patella in half, and locate its medial border
- Mark the injection site, just below medial patellar edge

## 2. Prepare Injection Site

- Clean site with povidone-iodine solution.
- Wipe with alcohol sponge

## 3. Inject Local Anesthesia

- Spray ethyl chloride over injection site. (*optional*)
- Use 5/8-inch 25-g needle and inject sufficient 1% lidocaine to form subcutaneous wheal
- Orient the needle parallel to the undersurface of the patella
- Insert needle toward the joint injecting 1 to 2-mL of lidocaine as needle is withdrawn

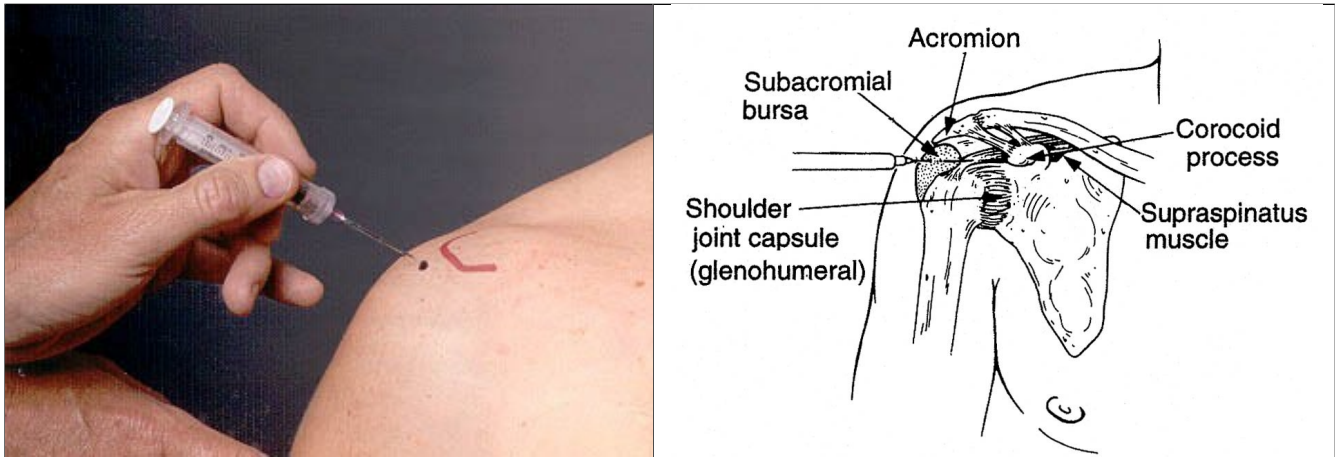
## 4. Remove Synovial Fluid

- With non-dominant hand, press on the lateral border of the patella moving it medially, this will enhance the joint opening
- Introduce a 1-½ inch, 18-g needle attached to adequately sized syringe into the joint
- Insert the needle parallel to the undersurface of the patella into the joint
- Stabilize the syringe/needle complex with the non-dominant hand in contact with the medial aspect of the thigh/knee and against the syringe
- Gently aspirate as much fluid as possible

**5. Introduce Steroids** (if indicated)

- Separate syringe from needle, keeping the needle in the joint
- Attach a pre-filled steroid syringe (see “Commonly Used Medicines” chart for dosage)
- Aspirate to determine location of needle
- If joint position confirmed, gently inject medication
- Remove syringe and needle, apply firm pressure with gauze
- Clean and apply band-aid

## Subdeltoid (Subacromial) Bursa



### 1. Identify the site

- Palpate the superior surface of the shoulder
- Move laterally until there is a slight drop-off; this is the lateral edge of the acromion
- The palpable soft spot below the acromion but above the humeral head is the location of the subdeltoid (subacromial bursa)
- Mark the site

### 2. Prepare injection site

- Clean site with povidone-iodine solution
- Wipe with alcohol sponge

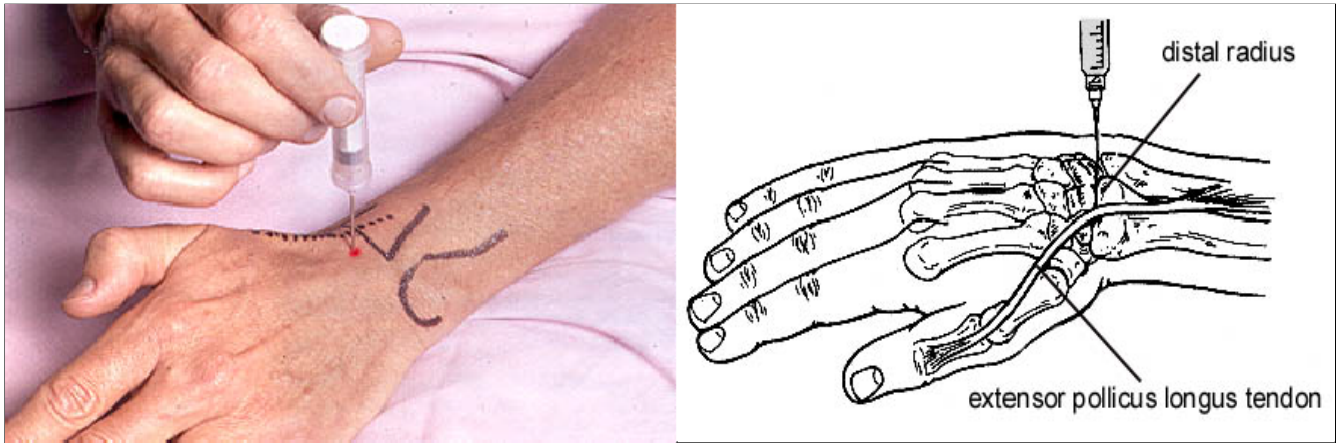
### 3. Provide local anesthesia

- Spray ethyl chloride over injection site (*optional*)

### 4. Introduce Steroids

- Attach a pre-filled 3-5 mL lidocaine-steroid-filled syringe to a 1 ½ inch, 25-g needle
- Direct the needle perpendicular to the surface through the deltoid muscle and into the bursa. Introduce the needle up to its hub
- The needle should be “free-floating” since it is within a space and not a muscle or tendon
- Before injection, aspirate to ensure the needle is not in a blood vessel
- Gently inject the medication (little resistance should be felt). If resistance is encountered, reposition the needle to avoid injecting directly into the tendons of the rotator cuff
- Remove syringe and needle, apply firm pressure with gauze
- Clean and apply band-aid

# Arthrocentesis of the Wrist



## 1. Identify the site

- Palpate the extensor pollicis longus tendon on the dorsum of the wrist as it crosses the distal radius. This can be easily identified by having the patient lift the thumb against resistance
- The injection site is the shallow depression on the ulnar side of the extensor pollicis longus, just distal to the distal radius
- Mark the site

## 2. Prepare injection site

- Clean site with povidone-iodine solution
- Wipe with alcohol sponge

## 3. Provide local anesthesia

- Spray ethyl chloride over injection site. (*optional*)
- Use 5/8 inch 25-g needle and inject sufficient 1% lidocaine to form subcutaneous wheal
- Insert needle toward the joint injecting 2 mL of lidocaine as needle is withdrawn

## 4. Remove synovial fluid

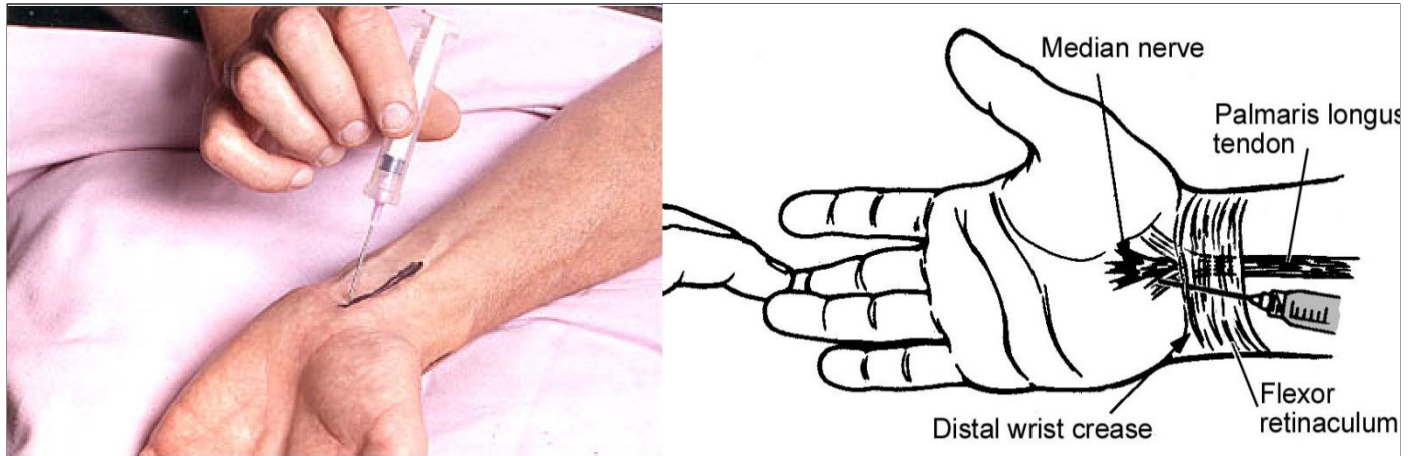
- Flex the joint to 20° to open the joint spaces
- With a 1 to 1 ½ inch 20 or 21-gauge needle attached to a 5 or 10 mL syringe, direct the needle into the joint, perpendicular to the mark. If the needle can be inserted 1.5 to 2 cm, it is correctly positioned in the joint space. The inter-carpal joints have interconnecting joint spaces, so this dorsal site can be used as a “universal site” for the wrist
- If bone is hit, withdraw the needle slightly and redirect slightly toward the thumb
- Gently aspirate as much fluid as possible

**5. Introduce Steroids (if indicated)**

- Separate syringe from needle, keeping the needle in the joint.
- Attach a pre-filled steroid syringe
- Aspirate to determine location of needle
- If joint position is confirmed, gently inject medication
- Remove syringe and needle, apply firm pressure with gauze
- Clean and apply band-aid

# Carpal Tunnel

---



## 1. Identify the site

- Dorsiflex the wrist 30° and rest it on a rolled towel or other support
- Identify the palmaris longus tendon by having the patient flex the middle finger against resistance
- Mark the site just medial (ulnar side) of the palmaris longus tendon

## 2. Prepare injection site

- Clean site with povidone-iodine solution
- Wipe with alcohol sponge

## 3. Provide local anesthesia

- Spray ethyl chloride over injection site (*optional*)

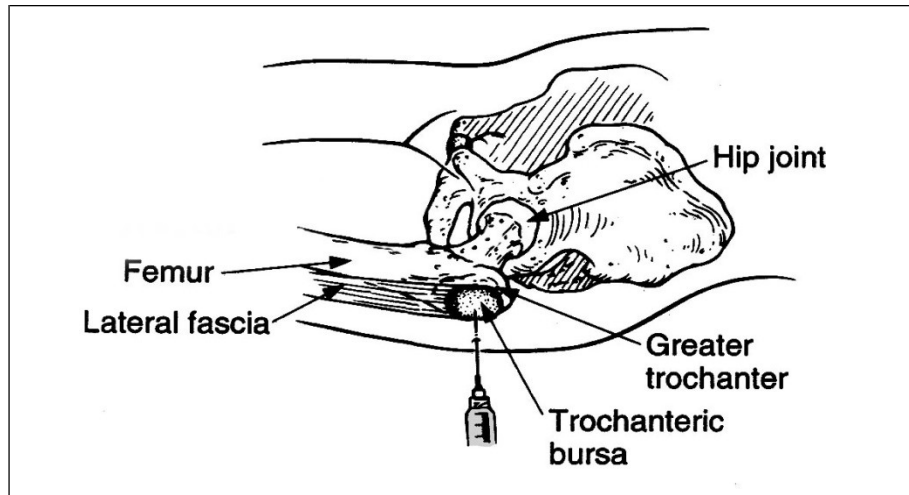
## 4. Introduce Steroids

- Attach a pre-filled steroid filled 1 or 3 cc syringe to a 5/8 inch, 25-g needle
- Angle the needle downward at a 45° angle toward the tip of the middle finger.
- Insert the needle at the distal wrist crease on the ulnar (medial) side of the palmaris longus tendon
- Insert the needle to its hub
- There should be no resistance to injection and minimal discomfort. If resistance is encountered, reposition the needle to avoid injection into the tendon
- Remove syringe and needle, apply firm pressure with gauze
- Clean and apply band-aid



# Greater Trochanteric Bursa

---



## 1. Identify the site

- Place the patient in a supine position with the leg in a neutral position
- Palpate the greater trochanter as a knob like structure
- Rotating the leg internally and externally will move the trochanter beneath the fingers
- Mark the site

## 2. Prepare injection site

- Clean site with povidone-iodine solution
- Wipe with alcohol sponge

## 3. Provide local anesthesia

- Spray ethyl chloride over injection site (*optional*)
- Create a subcutaneous wheal with lidocaine

## 4. Introduce Steroids

- Attach a pre-filled 3 mL steroid-filled syringe to a 1 1/2 inch, 25-g needle
- With the leg in a neutral position, apply pressure with the fingers of the non-dominant hand to compress the overlying tissue
- Direct needle directly down to the periosteum to inject the medication just above the periosteal surface
- Remove syringe and needle, apply firm pressure with gauze
- Clean and apply band-aid

## What to do with Synovial Fluid

---

Direct Observation	Comments
<p><b>Color</b> Yellow, pink, red or blood</p> <p><b>Turbidity</b></p> <ul style="list-style-type: none"> <li>▪ Clear - newsprint can be read through fluid</li> <li>▪ Slightly turbid - print is blurry</li> <li>▪ Turbid - print cannot be seen through fluid</li> <li>▪ Purulent - fluid is yellowish and/or thick</li> </ul> <p><b>Viscosity</b> String test can be performed with a drop of fluid between gloved fingers. Note the length of “thread” it makes as fingers are separated.</p>	<p>Normal synovial fluid is yellow or straw-colored: occasionally colorless</p> <p>Normal synovial fluid is clear. Turbidity depends on the presence of cells, fibrin, proteinaceous materials, cellular debris and crystals.</p> <p>Normal synovial fluid forms a 1-3” string. Record viscosity as normal, decreased, or increased. Note: Inflammatory fluid typically becomes less viscous unless grossly purulent.</p>

Tests that should not be ordered on joint fluid

- Mucin clot
- Total protein
- Viscosity
- Rheumatoid factor
- Anti-nuclear antibody
- Compliment
- Immune complex
- Red blood count
- Glucose

**If you have a small sample:**

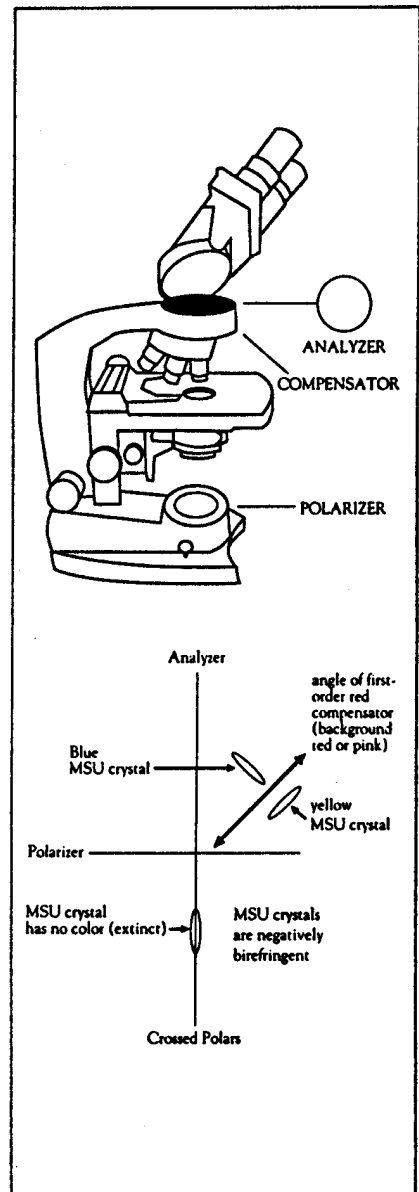
- Place one drop of joint fluid on a clean glass slide. Apply cover slip to top of the fluid. Examine under polarized microscopy for crystals. Estimate the number of WBCs. The slide can be separated from cover slip. Gram stain can be performed on the slide for presence of bacteria. Wright’s stain can be performed on the cover slip for cell count and differential.
- Cap the needle and send syringe immediately to the microbiology laboratory where the second drop of fluid can be plated for culture or inject remaining fluid in the syringe onto a sterile swab, place in culturette tube containing a holding media and send to laboratory.

## Tests to be ordered on joint fluid

<p><b>Cell count and differential:</b></p>	<p>Use green-top vacutainer (heparin) to prevent clotting and to preserve cell morphology</p> <ol style="list-style-type: none"> <li>1. <b>Leukocyte count</b> - Degree of leukocyte elevation indicates severity of inflammation <ul style="list-style-type: none"> <li>▪ Fluid with leukocyte count less than 2000 mm<sup>3</sup> are considered non- inflammatory</li> <li>▪ Fluid with leukocyte count more than 100,000 mm<sup>3</sup> should be considered infected</li> <li>▪ Fluid with leukocyte count between 50,000 mm and 100,000 mm may be either infected, due to crystals, or inflammatory (noninfectious) arthritis</li> </ul> </li> <li>2. <b>Differential leukocyte count</b> - Simply determine the percentage of neutrophils and monocytes <ul style="list-style-type: none"> <li>▪ Non-inflammatory fluid generally has less than 50% neutrophils</li> <li>▪ Infected fluid generally has more than 95% neutrophils</li> <li>▪ Non-infectious, inflammatory fluid has more than 50% neutrophils</li> </ul> </li> </ol>
<p><b>Microbiology:</b></p>	<p><b>Culture</b> - aerobic, anaerobic, gram stain and if needed AFB and fungal. Use red-top vacutainer (sterile, without additive) if fluid is sent directly to laboratory</p>
<p><b>Crystal Determination:</b></p>	<ol style="list-style-type: none"> <li>1. Examine a drop of synovial fluid under a coverslip by routine microscopy. Crystals can often be seen without a polarizing light microscope <ul style="list-style-type: none"> <li>▪ Urate crystals (gout) are needle-like, or blunt rods</li> <li>▪ Calcium pyrophosphate crystals (psuedogout) may be blunt rods or rhomboids</li> </ul> </li> <li>2. Proper polarized light microscopy requires both a high quality, well-maintained microscope and an experienced observer</li> </ol>

## Search For Crystals: How To Do It

- ◆ Take a clean slide and place a drop of synovial fluid from red top tube on a slide and cover with a clean cover slip.
- ◆ Study the cells under 100X and 400X magnification. Look for crystals of any size or shape.
- ◆ Polarize the microscope by turning the polarizer beneath the stage, Make the field become entirely "black" (this is when polarizer and analyzer are at 90° phase). The birefringent objects will appear bright. Gradually turn the polarizer to add a slight bit of light for orientation purposes. *Monosodium urate crystals* (MSU) will typically appear needle-shaped. *Calcium pyrophosphate dihydrate crystals* (CPPQ) will appear more pleomorphic:  
:with rods, often square-ended and parallel in clumps, which appear less bright.
- ◆ Positive identification of crystals with the use of first-order red compensator. Note the axis of the compensator lens, crystals which are parallel to the axis of the lens which appear yellow, are considered to be negatively birefringent. Conversely, crystals which are parallel to the compensator and appear blue are considered to be positively birefringent.
- ◆ Hint: YUP (yellow urate parallel) monosodium urate crystals, when parallel to the first-order red compensator, will be yellow and are considered to be positively birefringent.



## Commonly Used Medication Dosages for Joint and Soft Tissue Injection

Procedure	Triamcinolone acetanide (Kenalog) or hexacetanide (Aristospan)	Methylprednisolone acetate (Depomedrol)	Lidocaine 1%
-----------	---	---	--------------

### Arthrocentesis

▪ Knee	40 mg		
▪ Shoulder	40 mg		
▪ Elbow	20 mg		
▪ Ankle	20-30 mg		
▪ Wrist	20 mg	20 mg	
▪ CMC/MCP/PIP		5-10 mg	
▪ Acromioclavicular		5-10 mg	
▪ Sternoclavicular		5-10 mg	

### Bursal

▪ Subdeltoid	40 mg		2 mL
▪ Greater Trochanter	40 mg		2 mL
▪ Anserine		10 mg	2 mL

### Tendinitis Sites

▪ Bicipital tendon sheath	20 mg	20 mg	2 mL
▪ Lateral/medial epicondyle	10 mg	10mg	1 mL

### Trigger Point

▪ Intramuscular	5 mg	5mg	2 mL
-----------------	------	-----	------

### Miscellaneous Sites

▪ Carpal tunnel	10-20 mg		
▪ Tarsal tunnel	10-20 mg	10-20 mg	
▪ Costochondral junction	5mg	5 mg	1 mL

### **Preparatory Materials**

- Povidone-iodine (Betadine)
- Isopropyl alcohol (or individually packaged alcohol wipes)
- 4 x 4 sterile gauze sponges
- Latex gloves (vinyl if you or the patient has a latex sensitivity)
- Surgical absorbent pad (the blue "Chux" pad)
- Ethyl chloride spray (optional)
- Hemostat

### **For Local Anesthesia**

- 20-gauge, 1 inch or 1 1/2 inch needle
- 25-gauge, 5/8 inch or 1 1/2 inch needle
- 3 or 5 mL syringe
- 1% lidocaine hydrochloride

### **For Arthrocentesis**

- 18-gauge or 20-gauge needle
- 20 - 50 mL syringe, depending upon size of effusion

### **For Bursal Injections or Tendon Sheath injections**

- 25-gauge 1 1/2 inch needle
- 3-5 mL syringes

### **For Arthrocentesis and Bursal injections**

- Triamcinolone acetonide (Kenalog) or hexacetonide (Aristospan), or methylprednisone acetate (Depo-Medrol), see table on glucocorticoids: Intra-Articular Injections
- 3-5 mL syringes

### **For Joint Fluid Analysis**

- Red top tubes (no additives)
  - 1 for culture
  - 1 for crystal determination
- Green top tubes (sodium heparin) for cell count/differential
- Gray top tube (sodium fluoride) for glucose test (not routinely indicated)

### **Finishing up**

- Band-Aid
- Microbiology and cytology request forms
- OSHA approved sharps container
- Red plastic bag for contaminated materials

**To improve efficiency, physicians may find it useful to make up an arthrocentesis tray for the office.**

## Problems and Pitfalls

---

### **Lost the needle insertion landmark**

- Mark site of insertion with surgical pen
- Use thumb and finger of non-dominant hand to "frame" injection site after it has been marked

### **Needle strikes bone**

- Withdraw needle away from bone
- Redirect needle beneath surface of skin and insert

### **Needle is in joint, but fluid is difficult to aspirate**

- Fluid may be too viscous for needle
- Try with larger size gauge; 18-gauge

### **Fluid stops flowing**

- Tissue may be obstructing needle as joint volume decreases
- Try to reposition needle slightly
- If needle appears to be obstructed, re-inject a small volume of fluid, then aspirate again

### **Sitting patient appears pale, diaphoretic or complains of being faint**

- Stop procedure
- Immediately lay patient in supine position
- Support legs with table extension

## Comments

- If an EM visit is to be billed in conjunction with a procedure such as a joint aspiration or bursal injection, separate and different diagnosis codes must be used for the visit and the procedure (*Modifier 25 for the visit code must be used on the EM visit*)
- If an arthrocentesis is performed bilaterally, bill only one arthrocentesis procedure code and add modifier –50 in the injection code (*Bilateral knees 20610-50*)

- Modifier 59

Add a –59 modifier for each additional arthrocentesis procedure for separate (non-bilateral site)

For multiple joint procedures, payments will be reduced as follows:

2<sup>nd</sup> at 50%  
3<sup>rd</sup> at 25%

- Don't forget to bill for: triamcinolone  
10 mg/unit (J3301)  
methylprednisolone 20 mg/unit (J1020)

## General Information

### Documentation Requirements

The clinical record should include the elements leading to the diagnosis and the therapies tried before the decision to use injection. If the number of injections exceeds three, the record must justify these added injections since the presumed need for further injections should raise the issues of correct diagnosis or correct choice of therapy as well as concerns for adverse side effects.



# Primary Care Approach to Rheumatology

An Outline of the Important Elements to Elicit in a History and Physical Examination

**Clinical goals of rheumatological history and physical examination are to determine if the process is:**

- Articular or nonarticular
- Acute or chronic
- Monoarticular or polyarticular
- Inflammatory or noninflammatory
- Axial or peripheral
- Symmetrical or asymmetrical
- Limited musculoskeletal process or systemic process

## Elements to Elicit in a History

<b>Demographics</b>	<p>Age, sex and race are important.</p> <ul style="list-style-type: none"> <li>▪ Systemic rheumatic diseases usually begin in young and middle-aged women</li> <li>▪ Gout is infrequent in premenopausal women</li> <li>▪ Temporal arteritis is uncommon in blacks, SLE (systemic lupus erythematosus) more frequent</li> </ul>
<b>Social considerations</b>	<ul style="list-style-type: none"> <li>▪ Occupation and relation of work to symptoms</li> <li>▪ Workman's compensation claim or lawsuit</li> </ul>
<b>Pattern of pain</b>	<p>Determine if pain is:</p> <ul style="list-style-type: none"> <li>▪ Localized to joints or surrounding tissue</li> <li>▪ Generalized or localized to a single joint or area</li> <li>▪ Intermittent, acute, episodic or migratory and additive</li> </ul>
<b>Description of pain</b>	<ul style="list-style-type: none"> <li>▪ Muscle and joint pain may be "cramping" or "throbbing"</li> <li>▪ Neuropathic pain may be "burning" or "tingling"</li> </ul>
<b>Stiffness and fatigue</b>	<p>Helps differentiate inflammatory from noninflammatory conditions</p> <ul style="list-style-type: none"> <li>▪ Greater than 1 hour suggests inflammatory conditions</li> <li>▪ Early onset of fatigue suggests inflammatory condition</li> </ul>
<b>General symptoms are a clue to underlying disease process</b>	<p>SLE and other connective tissue diseases</p> <ul style="list-style-type: none"> <li>▪ Neurological symptoms, mucocutaneous lesions, photosensitivity, dry eyes and mouth, pleuritis, Raynaud's phenomenon</li> </ul> <p>Gout</p> <ul style="list-style-type: none"> <li>▪ Renal stones</li> </ul> <p>Reiter's syndrome, Behcet's disease, acute gonococcal arthritis</p> <ul style="list-style-type: none"> <li>▪ Genital ulcerations, penile or vaginal discharge</li> </ul> <p>Malignancy or infection</p> <ul style="list-style-type: none"> <li>▪ Fever, weight loss, anorexia</li> </ul>

## Physical Examination

The focus of examination is the musculoskeletal system, but a general physical examination can reveal helpful clues to diagnosis

	Symptoms	Causes
<b>Scalp, Skin, Nails and Hair:</b>	Alopecia, discoid lupus, psoriasis	Connective tissue disease Psoriatic arthritis
	Tender temporal artery	Temporal arteritis
	Malar rash, or sun-exposure rash	Connective tissue disease
	Psoriasis over elbows, knees, pitting of nails	Psoriatic arthritis
	Periorbital or dorsal hand rash	Dermatomyositis
	Generalized tightening of skin over hands, proximal limbs, trunk	Scleroderma
	Enlarging macular or papular rash with central clearing	Lyme disease
<b>Eyes and Mouth:</b>	Dryness of eyes and mouth	Sjogren's syndrome
	Changes in ocular fundi	Connective tissue disease or vasculitis
	Iritis or uveitis	HLA-B27 related disease
	Oral ulcerations	Connective tissue disease or Reiter's, Behcet's disease
<b>Pulmonary:</b>	Interstitial fibrosis	Scleroderma
	Pleuritis	Connective tissue disease
<b>Nervous System:</b>	Peripheral nervous system findings	Mononeuritis multiplex (i.e: foot drop) Vasculitis
	Central nervous system findings	Connective tissue disease, vasculitis or scleroderma
<b>Genitalia:</b>	Ulcers or discharge	Reiter's, Behcet's, or gonococcal infection

### General Physical Examination Findings of the Joints

- Observe and palpate for swelling, warmth, tenderness, crepitus
- Assess range of motion, passive and active
- Assess deformity such as ligamentous destruction, contracture, bony enlargement or subluxation

## Specific Joint Examination Checklist

### *The Spine*

---

#### 1. Cervical Spine

- Inspect for normal cervical lordosis

*Range of motion*

- 45° flexion  
 50° - 60°  
 extension 60° -  
 80° rotation 40°  
lateral flexion

#### 2. Thoracic spine

- Inspect for normal thoracic kyphosis

*Range of motion*

- Assess by rotation of shoulders with hips stabilized  
 Chest expansion at least 2 inches from full inspiration to full expiration

#### 3. Lumbar spine

- Inspect for normal lordosis

*Range of motion*

- Forward flexion - assessed by Wright-Schober test  
(A line measured 10 cm above to 5 cm below the iliac crest will normally lengthen 4 cm to 8 cm with forward flexion)

#### 4. Sacroiliac joints

Test for tenderness by palpation

- Direct pressure over the sacrum  
 Compression of the anterior iliac crest

### *The Shoulder*

---

- Assess symmetry between shoulders

Palpate for tenderness

- Lateral aspect of humeral head  
 Rotator cuff tendinitis  
 Anterior humeral groove  
 Biceps tendinitis  
 Acromioclavicular joint  
 Sternoclavicular joint

*Range of Motion*

- Raise arms above head in a wide sideways arc

- Raise arms in a forward arc, touch palms above head
- Touch top of head with elbows flexed
- Reaching back to touch midback area
  - If able to perform, suggests normal glenohumeral joint motion and intact rotator cuff
  - If unable to perform, do drop test for rotator cuff tear (patient unable to hold arm in the horizontal plane without support)

### ***The Elbow***

---

- Palpate for tenderness and swelling
  - Fullness in the area between the lateral epicondyle, radial head, and olecranon indicates joint effusion
  - Swelling directly over olecranon process indicates bursitis
  - Rheumatoid nodules may be found over the olecranon area and distal ulnar shaft

#### *Range of motion*

- Extension on the horizontal plane to 150° - 160°

### ***Wrist and Hand***

---

Palpate for tenderness and swelling

- Ulnar styloid for swelling and instability
- Cystic swelling over the dorsal aspect of hand
  - Ganglion cyst or tenosynovitis
- Flexor tendon sheaths, palmar fascia
  - Nodules or thickening (trigger finger)
  - Dupuytren's contractures

#### *Range of motion*

- Flexion to 90°
- Extension to 70°

Joints of the hand - Observe and palpate for tenderness, swelling and loss of movement

- Metacarpophalangeal joints
  - Involved in rheumatoid arthritis
- Proximal interphalangeal joints
  - Involved in both osteoarthritis and rheumatoid arthritis
  - Bony swelling referred to as Bouchard's nodes
- Distal interphalangeal joints
  - Involved in osteoarthritis and psoriatic arthritis
  - Bony swelling referred to as Heberden's nodes
- Grip strength
  - Can be objectively measured grasping partially inflated blood pressure cuff

- Nail abnormalities
  - Psoriasis, Reiter's syndrome

### ***The Hip***

---

Localization of hip pain

- Anterior hip pain
  - True acetabular disease
- Lateral and posterior
  - Wide variety of periarticular problems

*Range of motion* (patient supine)

- Flex knee and hip, then abduct laterally
  - Tenderness around lateral hip suggests trochanteric bursitis
  - Deep buttock tenderness suggests ischiogluteal bursitis
  - Tenderness in the anterior thigh or groin suggests hip joint pain or iliopsoas bursitis

### ***The Knee***

---

Inspect and palpate for tenderness and effusions

- Signs of effusion
  - Loss of lateral and medial "dimples"
  - Produce bulge sign on medial aspect of knee by gentle pressure on opposite side
  - Palpate popliteal fossa for cystic swelling
- Direct swelling over the patella (prepatellar bursitis)
- Direct tenderness over the infrapatellar tendon
- Tenderness along the lower medial aspect of the joint (anserine bursitis)
- Tenderness along the medial or lateral joint line (ligamentous or meniscal injury)
- Crepitus or clicking on passive motion due to meniscal damage

*Range of motion* (test with patient supine)

- Extension in the horizontal position to
- 0° Flexion to 130° - 150°

### ***The Ankle***

---

Inspect and palpate

- Inspect for effusions - can be detected as fullness anteriorly or swelling beneath either medial or lateral malleolus
- Palpate for tenderness near posterior heel (Achilles tendinitis or bursitis)

*Range of motion*

True ankle joint

- Flexion to 45°, extension (dorsiflexion) to 20°

Subtalar joint

- 20° to 30° of inversion and eversion

### ***The Foot***

---

Mid-foot

- Observe for abnormal configuration
- Palpation for warmth and tenderness

Anterior foot

- Palpation for tenderness across metatarsalphalangeal joints
  - Rheumatoid arthritis, osteoarthritis, gout

*Deformities*

- Inspect for lateral deviation of distal great toe at metatarsalphalangeal joint
- Inspect for dorsal subluxation of joints (hammer toes)

Plantar surface

- Palpate for tenderness along long axis, particularly at base of calcaneus suggests plantar fasciitis