

**American College of Physicians - Internal Medicine Meeting 2025
New Orleans, LA**

POCUS for DVT Diagnosis

Faculty Information

Director:

Douglas Joseph, DO

Syed Ahsan, MBBS, FACP



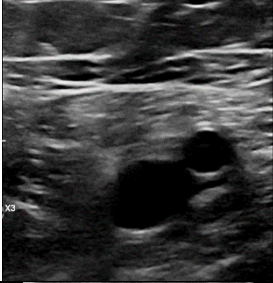
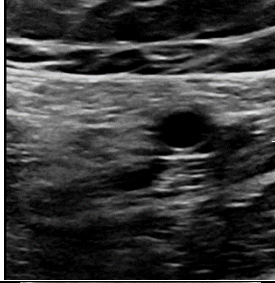


Debra R. Puffenberger, MSHS, PA-C, RVT

Posted Date: February 24, 2025

©2025 American College of Physicians. All rights reserved. Reproduction of presentations, or print or electronic material associated with presentations, is prohibited without written permission from the ACP.

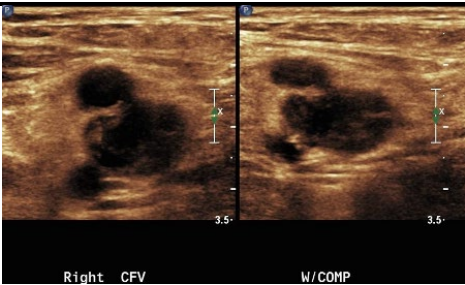
Any use of program content, the name of a speaker and/or program title, or the name of ACP without the written consent of ACP is prohibited. For purposes of the preceding sentence, "program content" includes, but is not limited to, oral presentations, audiovisual materials used by speakers, program handouts, and/or summaries of the same. This rule applies before, after, and during the activity

CLINICAL SKILLS CENTER - POCUS FOR DVT DIAGNOSIS 2025

		3 Point Protocol – Lower Extremity Venous Ultrasound Examination	
		Non-compressed	Compressed
Common Femoral Vein			
Femoral Vein			
Popliteal Vein			

*images above are from left leg

3-Point protocol: patient supine, hip externally rotated, knee flexed, 5-12 MHz linear transducer, begin at inguinal ligament, identify CFV, SFA, PFA, and GSV, compress CFV 1-2 cm increments, down leg through femoral vein until dives deep, then scan into posterior distal thigh compressing distal femoral and popliteal vein in 1-2 cm increments until reaching tibioperoneal trunk.

<p>Non-compressible vein is consistent with deep vein thrombosis</p>	
<p>*image of right common femoral vein acute DVT</p>	