

**American College of Physicians - Internal Medicine Meeting 2025
New Orleans, LA**

Toenail Removal

Faculty Information

Co-Director(s):

Kimberly Breglio, MD

Galen Foulke, MD, Member

Posted Date: February 24, 2025

©2025 American College of Physicians. All rights reserved. Reproduction of presentations, or print or electronic material associated with presentations, is prohibited without written permission from the ACP.

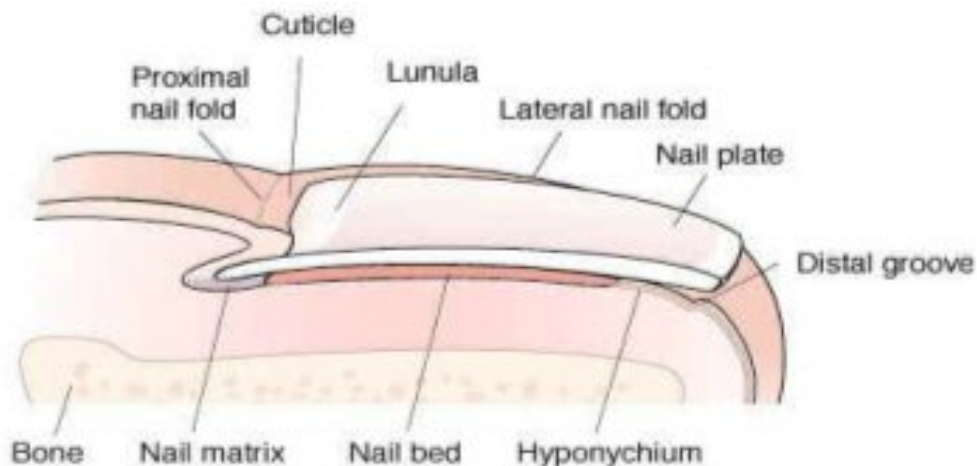
Any use of program content, the name of a speaker and/or program title, or the name of ACP without the written consent of ACP is prohibited. For purposes of the preceding sentence, "program content" includes, but is not limited to, oral presentations, audiovisual materials used by speakers, program handouts, and/or summaries of the same. This rule applies before, after, and during the activity

Nail Avulsion Basic Nail Anatomy and Surgery for the Internist

I. Nail Unit Anatomy

A. Nail Unit Terminology

- i. Nail Plate: Commonly referred to as toenail/fingernail
- ii. Proximal Nail Fold (PNF) : fold of skin on dorsal digit overlapping the proximal nail plate
- iii. Lateral Nail Folds (LNF): Folds of skin that overlap and support the lateral aspects of the nail plate
- iv. Lunula: the distal aspect of the nail matrix, visible as the white crescent beneath the proximal nail plate
- v. Nail bed: epithelium under the nail plate, extending from the matrix to the hyponychium
- vi. Hyponychium: epithelium under the distal aspect of the nail plate marking the end of the nail bed
- vii. Matrix: thick epithelium under the proximal nail fold responsible for production of the nail plate. The proximal matrix forms the top portion of the nail plate, the distal matrix forms the undersurface of the nail plate



B. Vascular Supply

- i. Lateral digital arteries divide into dorsal and ventral branches near distal interphalangeal space (DIP)
- ii. Ventral arteries extend distally, course around distal phalanx and form superficial and deep arcades
- iii. Vessels form arterial- venous (AV) anastomoses and AV shunts in the nail bed and matrix

C. Nerve Supply

- i. Paired palmar and plantar digital nerves parallel arteries to innervate nail bed, digital tip and pad

D. Nail plate

- i. Nail plate is a compact tri-laminar unit of keratin
- ii. Proximal matrix forms the dorsal nail plate
- iii. Distal matrix forms the ventral nail plate
- iv. Damage to the matrix causes nail dystrophy which could be permanent

E. Nail growth facts

- i. Fingernail growth: 0.1 mm/day, 3mm/month
- ii. Toenail growth: 0.03 mm/day, 1 mm/month
- iii. Nail growth is faster in
 1. men
 2. on middle digits
 3. on dominant hand
 4. in the summer
 5. during pregnancy
 6. after trauma, including nail biting
 7. psoriasis
- iv. Nail growth is slower during viral illness, lactation, and atopic dermatitis

II. Nail Disorders

A. Terminology

- i. Onychodystrophy: nail abnormality
- ii. Onychocryptosis: ingrown nail
- iii. Onychogryphosis: claw-like overgrowth of nail, usually caused by neglect
- iv. Onychorrhexis: longitudinal striations and ridging of nail plate
- v. Onychoschizia: layered splitting of free edge of nail plate
- vi. Onychauxis: hypertrophied thickened nail plate
- vii. Onychomadesis: shedding of nail plate from proximal end
- viii. Onycholysis: separation of nail plate from nail bed

B. Causes of onychocryptosis

- i. Excess curvature of nail plate
- ii. Hypertrophic skin of lateral nail folds or tip of digit
- iii. Congenital or acquired abnormal nail or digit shape
- iv. Trauma – e.g. improper nail trimming, tight fitting shoes
- v. Hyperhidrosis//sweating, esp. in adolescents
- vi. Medications – Isotretinoin, acitretin

III. Management of Ingrown Nails

- A. Temporary
 - i. Cotton wisp under corner of nail plate
 - ii. File or sand thickened nail plate
 - iii. Chemical thinning of nail plate using 40% urea
 - iv. Partial avulsion

- B. Permanent
 - i. Chemical matrixectomy
 - ii. Surgical matrixectomy

IV. Nail Avulsion – Indications

- A. Complete avulsion
 - i. Onychogryphosis
 - ii. Expose nail bed and matrix for nail unit biopsy to diagnose benign and malignant lesions or dermatoses
 - iii. Complete matrixectomy
 - iv. Treatment of subungual warts

- B. Partial avulsion
 - i. Temporary or permanent treatment of ingrown nails
 - ii. Paronychia associated with onychocryptosis
 - iii. Treatment of subungual warts
 - iv. Expose part of nail unit for biopsy

V. Nail Procedures

- A. Pre-operative considerations
 - i. Obtain pertinent medical history – diabetes, peripheral vascular disease, artificial heart valve, allergies to anesthetics
 - ii. Current medications – especially anticoagulants
 - iii. Obtain informed consent – risk of permanent nail dystrophy, infection, bleeding, pain, reoccurrence
 - iv. Counsel patient about post-operative course – time for regrowth, potential discomfort, activity limitations

- B. Supplies
 - i. Instruments – Freer septum elevator(nail plate elevator), nail splitter, hemostat, +/- curette.
 - ii. Anesthesia – 1-2% plain lidocaine, 3 cc syringes, 30 gauge needle, 0.5% bupivacaine
 - iii. Hemostasis – Penrose drain (tourniquet), cautery, aluminum chloride
 - iv. Misc – cotton tipped applicators or urethral swabs for phenol matrixectomy, gloves

- v. Dressings – petrolatum, non stick gauze, cotton tipped applicators, tape

C. Anesthesia tips

- i. Patient relaxation is critical for a successful procedure!
 - 1. Positioning – patient should be reclining in chair or flat, not sitting
 - 2. Relaxed atmosphere – music, calming demeanor of physician and nursing staff
 - 3. Reassurance
- ii. Administer anesthetic VERY SLOWLY using 30 gauge needle
- iii. Digital block – inject 1.0 - 1.5 cc at proximal aspect of digit. Inject midway between dorsal and ventral aspects. Goal is to bathe the digital nerves proximally with anesthetic. Less painful than distal injections
- iv. Allow adequate time for anesthetic effect , approx 10-15 minutes, this is critical
- v. Supplement with wing block if needed – inject anesthesia near junction of lateral and proximal nail fold. Supplement locally as needed
- vi. Assure that digit is completely numb prior to procedure.

VI. Complete Avulsion

- A. Administer anesthesia, and allow adequate time for effect. Verify that digit is numb, and if not, add supplemental anesthesia
- B. Prep digit – this is a clean but not sterile procedure. Betadine, chlorhexidine, or alcohol can be used.
- C. Insert freer septum elevator beneath nail plate, and gently push proximally separating the nail plate from the nail bed, until there is a sudden decrease in resistance. Aim the elevator upwards, against the undersurface of the nail plate, using care not to damage the nail bed or matrix.
- D. Remove the elevator, and reinsert again. Repeat until nail plate is completely separated from the nail bed.
- E. Use the elevator to separate the proximal and lateral nail folds from the nail plate.
- F. Using a hemostat or nail pulling forceps, grasp the nail plate, and roll laterally to free the most lateral and proximal aspects of nail plate, then pull, and remove the nail plate.
- G. Curette debris or granulation tissue if present.
- H. For hemostasis, apply direct compression for 10 minutes, cauterly and/or aluminum chloride
- I. Consider injecting 0.5% bupivacaine to prolong anesthetic effect
- J. Apply pressure dressing with petrolatum, non adherent gauze, additional gauze for drainage and cushioning

VII. Partial Avulsion

- A. Administer anesthesia
- B. Prep digit
- C. Insert freer septum elevator under lateral free edge of portion of nail plate to be removed.
- D. Gently advance elevator to proximal aspect of unit.
- E. Using nail splitter, with flat side along nail bed, and blunted tip on top, advance along nail plate to proximal aspect. Gently insert blunted edge underneath proximal nail fold.
- F. With scissor like action, cut the nail plate
- G. Use hemostat to remove lateral aspect of nail plate, in rolling motion, being sure to remove lateral and most proximal aspect of nail plate.
- H. Curette any debris or granulation tissue.
- I. Obtain hemostasis with pressure, cautery, and/or aluminum chloride.
- J. Apply petrolatum, non- adherent dressing, and gauze.

VIII. Chemical matrixectomy (phenol)

- A. Phenol (carbolic acid, 88%) can be used for a chemical matrixectomy, partial or complete.
- B. Phenol must be kept fresh, in a dark jar, and requires a BLOODLESS field for effect.
- C. After complete or partial nail avulsion, obtain hemostasis with pressure or tourniquet
- D. Using a cotton tipped applicator or urethral swab, apply phenol to the lateral and proximal corners of the nail matrix (or complete matrix).
- E. After 30-45 seconds, rinse with alcohol or sterile water.
- F. Repeat steps D & E (total of 2 applications of phenol)
- G. Consider applying petrolatum to the proximal and lateral nail folds, before applying phenol, to protect these structures from damage
- H. Bandage as above.

IX. Wound Care

- A. Some discomfort is to be expected within 1-2 hours.
- B. Analgesic give at the time of surgery could be considered – acetaminophen
- C. Elevation of the leg is very important to minimize pain – keep foot up on stool when sitting, consider a pillow under foot at bedtime.
- D. The patient may apply cool compresses (ice pack)
- E. Daily soaks could be considered if there is drainage or debris.
- F. The wound should be washed daily with warm soapy water.
- G. The wound should then be dried thoroughly, petrolatum applied, and covered with non-adherent dressing. Additional gauze can be helpful for drainage, and cushioning.
- H. Consider giving the patient a prescription for pain medicine to have on hand.

Nail Surgery Codes

Avulsion of a nail plate (codes 11730 and 11732) is generally performed under local anesthesia and involves the separation and removal of a border of, or the entire nail from, the nail bed to the eponychium.

Excision of nail and nail matrix (code 11750) is performed under local anesthesia and requires removal of part or the entire nail along its length, with destruction or permanent removal of the matrix (e.g., chemical/surgical matrixectomy).

Wedge excision of skin of nail fold (code 11765) is designed to relieve pressure on the nail/soft tissue and requires an excision of a wedge of the soft tissue and ingrown nail from the involved side of the toe.

Debridement codes (11720, 11721) when actually performing routine foot care,

References

Title XVIII of the Social Security Act, Section 1862 (a)(7). This section excludes routine physical examinations.

Title XVIII of the Social Security Act, Section 1862 (a)(1)(A) states that no payment shall be made for items or services which are not medically reasonable and necessary.

CMS On-Line Manual Pub. 100-2, Chapter 15, Section 290

www.cms.gov or www.medicare.gov

ICD-10 Codes

L60 Nail disorders

L60.0 Ingrowing nail

L60.1 Onycholysis

L60.2 Onychogryphosis

L60.3 Nail dystrophy

L60.4 Beau's lines

L60.5 Yellow nail syndrome

L60.8 Other nail disorders

L60.9 Nail disorder, unspecified